Let's talk lasers: part two

Dr **Arun Darbar** and Dr **Rita Darbar** Smile Creations Dental Innovations continue their series of articles and discuss hard and soft tissue laser dentistry

As clinicians we are constantly striving to improve the treatment delivered and outcomes for our patients. At present, conventional methods for treating common dental disease are associated with pain by patients, annoying drilling vibrations and bleeding which can deter them from seeking the treatment that they need. The purpose of this article is to demonstrate that lasers can be a viable alternative to deliver treatment that is less painful (Charoenlarpa et al, 2007), vibration free (Takamori et al, 2003) and effective haemostasis (Coluzzi 2008). For the practitioner, lasers offer other advantages such as removal of the smear layer from dentine surfaces (Takeda et al 1998) and reduction of bacteria in periodontal pockets (Ando et al 1996). The following cases treated in our practice utilise these benefits both for the patient and the practitioner. To us, this represents the ultimate in comfort, standard and the quality of care our patients will probably expect and be prepared to pay for in these difficult times with financial restrictions all around us.

Dr Arun Darbar has been using lasers in his dental practice for the past two decades. He has his private practice Smile Creations in Leighton Buzzard, Bedfordshire. He is dedicated to providing cutting edge dentistry to his patients and is an examiner for the Academy of Laser Dentistry and is on the credentialing committee of the British Academy of Cosmetic Dentistry. A founder member of the World Clinical Laser Institute, he continues to find newer applications for the lasers and lectures extensively on the subject. He also runs courses and trains dentists both in the UK and internationally.

Dr Rita Darbar runs her Specialist Orthodontic practice and is also a Specialist Orthodontist at Bedford Hospital. She has had a varied career in dentistry spanning over 30 years, working in the community Dental services, General practice and Hospital services. She enjoys working in a multidisciplinary environment has been interested in laser dentistry for the past eight years and has talked on the subject internationally.

Education aims and objectives

The aim of this article is to demonstrate the advantages of using lasers in dentistry.

Expected outcomes

The reader will understand, through a series of case studies, the excellent results produced when using lasers.

Traditional lasers were an expensive item, but today there are economical units available. We have never regretted getting involved with them and are always looking at newer better models or alternatives. It is similar to playing golf - you just get hooked!

The examples we demonstrate here are just a few preview items and we feel the question is 'not about whether one can afford to buy a laser or not, but it's about whether one can afford to be without one!'.

Having a thorough knowledge in the workings of a laser and adequate training are part and parcel of its everyday use and should not be ignored. There is a learning curve in everything we do, and a slight shift in paradigm.

Traumatic injuries to teeth affect about 8% of children with 80% of those involving the maxillary incisors (Zerman and Cavalleri 1993). Most injuries are a result of an accident, mainly during play and sporting activity. As the maxillary incisors are the most commonly affected teeth the efficient management of these cases is vital for optimum long-term prognosis. The anterior teeth are important for appearance and function. Treatment is aimed at reducing pain, restoring aesthetics and function. There is also a need to avoid complications as these may result in a loss of the tooth leading to bone loss and compromising aesthetic replacement of the tooth. Lack of co-operation of the child can also be a factor that determines the final outcome of the treatment.

Case report 1

An 11-year-old boy was referred to the practice for the treatment of a traumatic injury to the permanent upper left maxillary incisor by his GDP. The child was on vacation when this happened and saw his GDP when he returned a couple of days later. The child was very apprehensive and as the pulp was involved he was in pain. Pulp extirpation was attempted but the child refused to have a local anaesthetic and it was not possible to treat him, hence the referral.

On examination extra-orally, there was soft tissue injury to the lip which was swollen and lacerated. Intra-orally the child presented in the mixed dentition stage of development. The UL1 had lost more than two thirds of the clinical crown on the facial aspect and the fracture extended sub-gingivally on the palatal aspect approximately 3 to 4 mm below the CEJ. The enamel, dentine and the pulp were involved. The oral hygiene was fair and there were no restorations present.

Treatment proposed

Endodontic treatment of the tooth followed by restoration of the tooth.

- Root canal treatment
- Low Level Laser Therapy (LLLT)
- Laser endodontics and post and core build up, followed by direct composite build up
- To reassess and observe until the child is older, then consider other long term solutions, such as crowns and implants. Needs orthodontics.

Possible alternatives

Extraction, upper denture, Maryland bridge, conventional bridge or implant, root canal treatment, post and core build up, reassess and orthodontics. Use rotary instruments and laser for hard tissue and endo, and LLLT. Orthodontic extrusion of the tooth up to the fracture level and crown at a later date.

Case report 1

Figure 1: At initial examination

Figure 2: Retracted view at examination

Figure 3: Fracture lines close up view with irritation

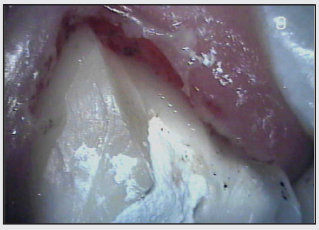

Figure 4: Laser Tissue recontouring and reshaping exposed sharp margins

Figure 5: Tissue healing in a week

Figure 6: Laser endo

Figure 7: Root canal filled tissue look healthy

Figure 8: Post space created and cleaned with laser

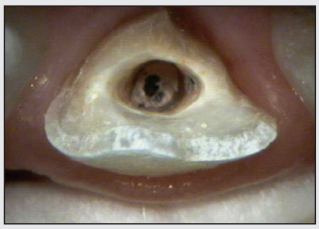

Figure 9: Laser surface modification for post and core build up

Figure 10: Laser surface modification for post and core build up

Figure 11: Composite fibre glass post and core in situ

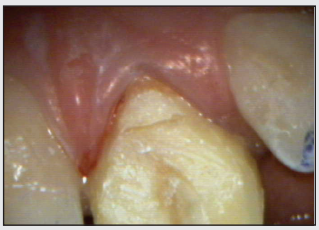

Figure 12: Core build up for final restoration

Figure 13: X-ray at examination

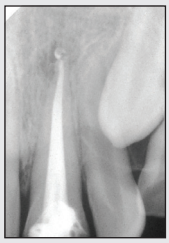

Figure 14: Post endo

Figure 15: On completion of restoration

Figure 16: At +2 year review

Figure 17: Immediately on completion of restoration

Figure 18: At 2 Year review

Figure 19: At 2 year review

Case report 2

Figure 20: Pre-op

Figure 21: Close up pre treatment

Figure 22: Completed restoration

Case report 3

Figure 23: Pre-op

Figure 24: Close up fractured incisor

Figure 25: Completed restoration

*Lasers used for Hard and Soft Tissue and LLLT in this treatment are Er.Cr.;YSGG 2780nm and Diode 810 nm.

Laser indications

As the child had a fear of needles, laser analgesia was indicated and pain and healing enhancement using PhotoBioModulation (PBM) would be appropriate.

- A combination of various wavelengths to help this boy come to terms and accept dentistry in general.
- Provide minimally invasive techniques, reduce vibrations and trauma as much as possible.

Objectives

- To provide a non traumatic experience to gain the patient's confidence.
- To make this complex procedure as comfortable as possible appropriate to this 11-year-old child.

Visit 1

The child was prescribed Metronidiazole for the infected pulp and digital x-rays taken to assess the damage and to check for root fracture. The radiograph confirmed that the root was not fractured, the bone intact and the apex was closed. Photos were taken for records and the patient was treated with the diode laser for pain management (Kudoh et al 1989) and to familiarise the child with the lasers.

Visit 2

Root canal treatment was commenced, as the child was now calmer knowing that the treatment would be carried out without injections. The canal was prepared using a laser 2780nm delivered through a 200-micron fibre.

There was a fragment of fractured enamel on the palatal aspect causing irritation to the gingival tissue that was inflamed. The laser was used to excise the excess gingival tissue and to remove the fragment. The child remained calm and was comfortable throughout the procedure.

Visit 3

The canal was widened and decontaminated using the hard tissue laser 2780 nm for the preparation (Hadley et al 2000) and the 810nm diode for the decontamination (Moritz 1999). The hard tissue was prepared minimally to smooth the edges to avoid trauma to the soft tissue.

Visit 4

The root canal was filled using thermoplastic material and a periapical x-ray was taken. The patient was treated with the diode laser for a low level effect to accelerate inflammation, reduce postoperative pain and enhance healing (Hopkins et al ?).

Visit 5

Fibre post and core build up and the tooth prepared for restoration. The hard tissue laser 2780nm was used for this and the tooth restored to its former anatomy using enamel plus shades A1/B1 and an impression taken for a mouthguard.

Visit 6

Mouthguard fitted and photos taken.

Visit 7

12-week review and periapical radiograph.

Visit 8

Two-year review periapical radiographs.

Conclusion

The use of lasers offers an alternative to conventional treatment for the unco-operative child.

Case report 2 and 3

Class IV fractures

In simple cases of just enamel and dentine fracture it is possible to disinfect, clean and modify the surfaces of the tooth or teeth with the hard tissue laser and using the standard enamel and dentine bonding protocols to restore using any of today's excellent composite materials, most of this being non invasive can be provided without the need of an injection which for most children is most terrifying part of the whole procedure.

Case report 4

Failed pinned composite

This case demonstrates the precision with which we can use the hard tissue laser to remove the composite resin from around retentive pin and replace composite after laser surface modification and without use of anesthesia.

Case report 4

Figure 26: Retracted view of pinned restoration

Figure 27: Pre-op smile

Figure 28: Close up

Figure 29: Laser composite removal

Figure 30: Post-op smile

Figure 31: Close up finals

Case report 5

Figure 32: Full arch Pre-op

Figure 33: Lower Right Close up view Pre-op

Figure 34: Lower left close up Pre-op

Figure 35: Full arch Post-op

Figure 36: Post-op

Figure 37: Post-op

Amalgam replacements

Lasers at present cannot be used to remove any metallic restorations, hence conventional rotary instrumentation is used, followed by tooth surface modification and preparation with the hard tissue laser. Conventional bonding protocols are followed by either direct or indirect composite or ceramic restorations. Lasers can efficiently remove composite very accurately, can also be used for glass ionomers but tend to leave a dark film depending on the glass ceramic content.

Case report 5

Introduction and chief complaint

This patient had some aesthetic treatment nearly eight years ago, and was going to continue with the same for the amalgam replacements, but due to personal reasons, could not. She had maintained her teeth on irregular basis, and now was concerned about the dark blue /grey appearances in the lower teeth (amalgam restorations present) and the upper teeth were lighter than the lowers and wanted the lowers to be the same or close. The options of whitening and amalgam replacement were considered.

Lower arch treatment plan

Laser curettage: Replace the leaking amalgams with direct composite resin restorations and provide home trays along with an office power whitening for this patient.

Under normal situations, provision of whitening would precede any restoration replacement, but in this case due to the amount of the posterior enamel involved within the resto-

Case report 6

Figure 38: Pre-op upper left

Figure 39: Template marking Zenith

Figure 40: Laser marked gingival margins

Figure 41: Laser ablated tissue

Figure 42: Temps at two day post-op

Figure 43: Final restoration at fit appointment

Figure 44: Final restorations at four weeks post-op recall

ration, appeared to be limited. A decision was made to replace the amalgams first, and then provide whitening with a provision to modify the surfaces if needed.

Treatment provided

Laser curettage using diode laser and using principles of Photo Modulated Periodontal Therapy (PMPT) (Ando et al 1996, Darbar 2006). The amalgam replacement was to be provided, using the 'Vanini technique' (Vanini 2006) of sectional build-ups in small increments to overcome the 'C' factor and cuspal flexing. The amalgams were removed using a rotary instrument and bur, using a high magnification 4 -10 under a microscope and without any anesthesia. The patient was offered LA as normal, but had previous experience here in the practice without LA, by using the Laser to precondition the treatment area, and the patient was happy for us to do so again, to produce an analgesic effect.

A butterfly throat sponge was used to trap the amalgam, as the patient was not comfortable with claustrophobic sensation of the rubber dam. Once the amalgam was removed, the teeth were prepared for enamel bonding, decontaminated, and bevelled with a hard tissue laser at specific protocols. Enhanced bonding (Apel and Gatnecht 1999) can be produced using laser and acid etch together. The total etch technique was used and the teeth were restored individually from start to finish.

At the end of that appointment, impressions were taken for the next stage of whitening for both home and surgery whitening, which was completed two weeks later and followed up with four week recall. The patient was happy with the results, and we were able to complete the procedure with minimal invasive procedures to restore the old teeth effectively. Working with high magnification, illumination and lasers was an effective combination.

Gingival recontouring and crown lengthening

Gingival recontouring can be achieved very efficiently and conservatively with lasers, soft tissue modification is possible with diodes and hard tissue lasers, however if any osseous recontouring is required then the hard tissue laser is the instrument of choice. The principles and concepts of biological width have to be adhered to. There are several techniques possible but ideally use your technique and modify it for laser assisted techniques, as this the best and fastest way to learn and put lasers into practice. In instances where a minimum amount of soft tissue is to be removed it can be done on the day of the preparation of the restorations provided a finely finished temporary restoration depicting the final gingival margin is to be used or constructed.

When complex and multiple teeth are involved a combination of conventional and laser techniques work better and normal protocols of periodontal surgery should be adhered to allowing enough time for adequate reorganization and maturation of the tissues prior to placement of final restorations. Conservative closed or flapless and open techniques can be used depending on ones knowledge and experiences with different wavelengths.

Case report 6: Laser gum recontouring at UR45

Introduction and chief complaint

Patient had fractured one of the old composite restorations, others had discoloured and patient was conscious of the size and shape of the anterior teeth. Patient had both upper lateral incisors congenitally missing and had orthodontics for space closure and the canines were repositioned in the laterals position and other teeth moved into more favorable positions. She also wanted whiter teeth with natural morphology. The patient is a healthy 20-year-old female with no medical complications or contraindications.

Smile evaluations indicated

Tooth size and shape discrepancies with more gingival tissue visible on the right then the left, spacing present between all anteriors, height to width ratios not within normal levels and appearance. There appears to be a slight facial asymmetry but dental midlines are normal, with an occlussal cant.

Treatment options

We chose the provision of restorations (bond-

Case report 7

Figure 45: Pre-op soft tissue recontouring

Figure 46: Immediate Post-op after laser ablation

Figure 47: Temps at immediate post preps

Figure 48: Temps at one week post preps

Figure 49 and 50: Final restorations

ed porcelain veneers and three quarter crowns) (Magne et al 2000) with minimally invasive procedures and recontouring of soft and hard tissues. Since the patient is now of a suitable age a long-term solution was considered with minimally invasive procedures, as restorations were needed mainly due to missing tooth structure.

A routine oral hygiene phase maintenance was established first as a base line requirement before any treatment could be contemplated. A soft tissue diode was used. It was imperative that a week or so was allowed before whitening procedure to avoid any sensitivity problems (Greenwall 2000). A tray system was used and favored as patient was a student and coming up for final exams using a 9% hydrogen peroxide buffered gel over a four-week period. On completion of whitening a further two-week period was allowed for normalisation. A desensitisation pack was also included in her whitening kit.

Tissue recontouring was performed with the aid of a hard and soft tissue laser at UR4. UR5, UL5 using specific laser protocols and using the biological width (Ingber et al 1977, Tarnow et al 1992) principals, at the prep appointment UL5,UR4 needed very little modification of the cervical margins and was all soft tissue based, the UR5 needed some bone removal but this was kept to a minimal level taking into account the patients age and expected normal gingival change.

The veneers and crowns were fabricated in Pressed Authentic ceramic ingots build and layered authentic enamel and effect porcelains. The restorations were bonded to enamel and dentine (WET) using current etch and bonding protocols, the abutment fitting surface was also hard tissue laser treated at very low powers to enhance bonding and smear layer removal (Apel and Gutnecht 1999, Magne et al 2000, Greenwall 2000). The fitting surface margins were not laser treated to avoid any discrepancies in fit or sealing of restorations). A dual cured resin cement was used for the final cementation using normal wet bonding protocols.

Conclusion

This minimally invasive treatment will last her for years and still has the option of more radical treatment should she need it in the future.

Case report 7

A simple case of soft tissue crown lengthening can be done with any of the diodes available today and hard tissue lasers. In a situation like this involving a single tooth the modification can be provided at the preparation appointment with effective temporisation and can take but a few seconds to minutes and can be combined with gingival troughing prior to final impressions.

Laser whitening

Laser whitening is effective if the right materials are used i.e. each laser manufacturer has their own propriety mixes for their lasers and specific to the wavelength, since these are chromophore targeted gels, one should follow the guidelines set by the manufacturer. These gels are high in hydrogen peroxide concentration (35%-40%) similar to power whitening materials hence tissue management and protection are crucial for patient comfort and acceptance. The efficacy of the system is really noticeable in internal whitening procedures, and a combination of mild home kits and laser in office materials prove to show the best results. In the past year or so there has been a lot of research in this field and we await the final results, there has also been a move to producing non wavelength specific gels fit for all lasers however, the instructions given to follow your own laser's protocol, raise a lot of questions in our minds, we have used it mainly for curiosity rather than need.

Since whitening is a commonly required treatment procedure we have to keep a breast of the developments and advances, from our pilot cases we feel there will be a move towards lower concentrations with longer times and specific protocols and regular maintenance program.

Laser endodontics

Laser endodontics was perhaps the first field of major laser research in the decontamination of the root canals, in fact a paper was published in the early nineties from Bristol Dental faculty proving in vitro studies of 99% bacteria kill us-

Case report 8

Figure 51: Pre-op Smile

Figure 52: Pre-op retracted view

Figure 53: Close up pre treatmnet

Figure 54: Single visit laser endo and space for internal whitening

Figure 55: First stage internal and opening chamber

Figure 56: Close up and first stage whitening

Figure 57: Completion of whitening

Figure 58: Post whitening close up

Figure 59: Final restorations smile

Figure 60: Close up finals

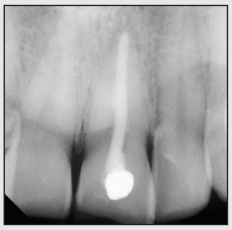

Figure 61: Original RCT

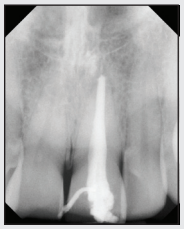

Figure 62: Immediate RCT filling

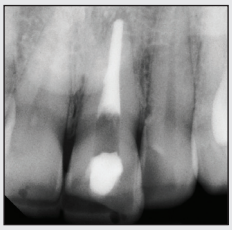

Figure 63: RCT with whitening and post space and chamber

ing the first dental laser using Nd:YAG 1064 nm wavelength. Today several wavelengths are used for the same purpose and numerous studies with its effect on "E Coli'. Comparisons have also been made for lateral canal penetration depths using different wavelengths and laser systems, in general the diodes and Nd:YAG have better penetration than the hard tissue lasers but both laser types have better penetration than conventional hypochlorite solutions.

In recent years FDA approval has been granted to manufacturers for complete endodontic treatment that is both for decontamination and preparation of root canal surfaces. Traditionally the soft tissue lasers utilise 200 micron fibres with effective heat component but are limited in end firing fibres so revolving action is necessitated to cover as much root surface as possible, there will be further modification in this field with the advent of active photo disinfection concepts. Advances in tip designs with side firing or radial firing tips, which reduces penetration through the apex, and concepts of photo acoustic streaming have been gathering momentum. Combinations of different lasers (wavelengths) for this particular treatment modality will and can improve the treatment outcome and acceptance, comfort for our patients especially if one is to combine the high and low energy protocols and perhaps the preconditioning to be discussed in Part Three of this series.

Case report 8

Use of multiple wavelength lasers for replacement composite restorations. The main concern for the patient was the upper left central incisor, which appeared darker on photographs. As she was going to be the bridesmaid, this motivated her to do something about it.

She had been given options to replace the old composites, and being endodontically treated, the UL1 appeared dark in colour. The options considered were related to veneers and crowns and possible whitening as well.There is a history of a bike accident in childhood and repairs with composites and an amalgam palatal seal. UR1 had a mesio incisal composite restoration as well. Her main concern was the UL1, but was happy with the remaining teeth for now, and would seek advice for the remaining teeth in time, as the urgency was this discoloured incisor.

The possibility of orthodontic treatment was discussed, and as she would consider it at a later date, a very conservative approach and maintaining tooth anatomy became an

Case report 9

Figure 64: Laser gingival troughing

Figure 65: Anterior abutments, laser surface modification

Figure 66: Posterior abutments laser modified

Figure 67: Full arch view of abutments and bridge span

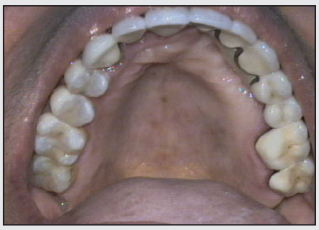

Figure 68: Bridge in situ

important issue. The options considered were whitening, veneers, and crowns. However as a long-term consideration and the possibility of orthodontics, it was agreed that a simple conservative solution would be more suitable.

The root filling provided previously was adequate but lacked an effective seal, hence it was decided to re-treat and prepare it with an initial seal to be able to provide internal whitening (Christansen 1997), follow up with home and power whitening before replacement of the restoration with composite resin was considered.

Oral hygiene instructions and a periodontal assessment was carried out and impressions taken for diagnostic models. Laser assisted endodontic re-treatment of the upper left incisor was commenced and the internal seal cavity modified for internal whitening. This was followed up with power laser whitening.

The upper incisors were prepared using a hard tissue laser and the restorations were then replaced with composite resin. Lasers were used for all the procedures and the wavelengths used were 2780nm, 810nm and 940nm.

Conclusion

The patient was happy firstly that we had completed the treatment before her big day, and the results to that were very acceptable, for us it was also having the possibility to better the final results with orthodontics and modifications without major reconstruction of work already provided. Now we wait for the next stage.

Gingival troughing

It is possible to use lasers to achieve the same effect as placing a cord around crown, veneer, inlay preps prior to taking of final rubber based impression. This can be achieved by use of either just soft tissue laser or hard tissue laser and a combination of both is also possible depending on tissue types and weather any crown lengthening is also required.

Case report 9

In this particular case a combination technique was used and laser surface modification of the fitting surfaces of the teeth abutments for enhanced bonding was also possible.

Periodontics

Lasers used today in periodontal therapy are the erbium family and Diodes 800-980nm and diode 1064 nm Nd:YAG 1064 nm.

The technique used for laser curettage is called 'Photo Modulated Periodontal Treatment' PMPT (Darbar 2006). This technique was developed by us and has been used for last two decades. It is used to stimulate repair and regeneration and used in pockets to remove soft plaque and reduce bacterial counts (Moritz 1999, Ando et al 1996) and biostimulate gingival tissues. An ultrasonic scaler facilitates physical removal of irritants including bacteria and calcified plaques from tooth and root surfaces. This is accomplished primarily by use of soft tissue lasers with a 320-400 micron fibres. Recently hard tissue lasers have also been approved for similar treatment but with the added advantage of being able to be used around osseous tissues, and these also use the 200 micron radial firing tips.

The laser curettage can be modified for different classifications of periodontal disease depending on the severity of the problem and a combination of conventional surgical and non-surgical treatment is also possible, however use of laser does reduce the need for an aggressive surgical approach. There are several schools of thought regarding the laser periodontal management and treatment depending on the disease classification type 1,2,3,4. Many techniques have been adapted or described but essentially have the same aims, which are: Reduce bacterial activity, Promote healing and repair, Reduce pockets (Yamaguchi et al 1997, Schoop et al 2002) hopefully regenerate bone or at least stop further breakdown, Reduce pain and swelling, and maintain and stabilise.

Research and clinical case studies indicate that certain lasers, adjunctively used with scaling and root planning, can improve the effectiveness of phase one periodontal therapy. Lasers can disinfect (Ando et al 1996) detoxify (Sasaki et al 2002), remove calculus (Keller et al 1995, Frentzen et al 2002) (erbium family) and help with regeneration.

The most important part of any periodontal therapy is home care and maintenance but for this patients need motivation and the fact that most patients find routine scaling rather painful or sensitive does keep them away from our maintenance visits, however use of laser curettage techniques also reduces their discomfort during and after treatment depending on protocols used, as several cellular mechanisms

Case report 10

Figure 69: Pre-op at examination

Figure 70: Pre-op

Figure 71: Close up view of damage and inflamed tissue

Figure 72: Midway treatment, second session

Figure 73: Midway stage

Figure 74: After the fourth session

Figure 75: After the fourth session

Figure 76: At the fourth session

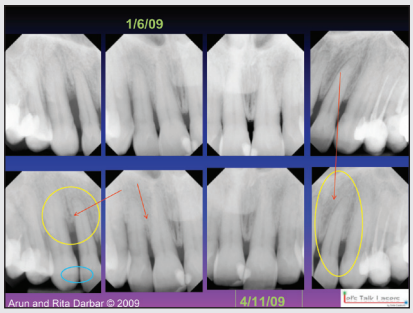

Figure 77: X-rays pre treatment and Nov. recall on slide (left)

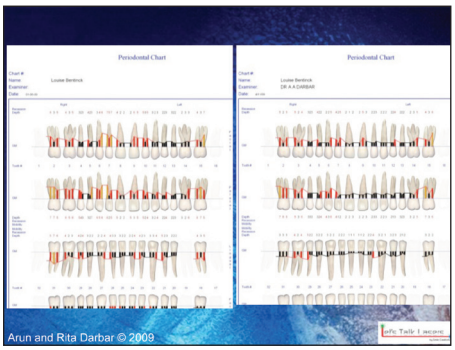

Figure 78: Two pero charts comparision

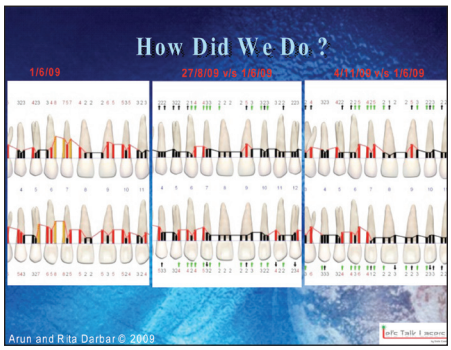

Figure 79: Three perio chart comparision

Figure 80: Midway chart comparision to start of treatment

come into action on the use of lasers in non surgical mode. Lasers can be combined with all forms of conventional periodontal therapies.

Case report 10

This is a case of advanced periodontitis class IV type with bone and soft tissue breakdown, suppuration and bleeding on touch and UR2 and 3 were mobile grade 2/3 with vertical and horizontal components. Some of pockets were in 8-9 mm range. This patient found us because of our laser involvement, and traveled from East Sussex hence long appointment sequences were arranged over a period of time rather than regular and frequent visits.

Treatment provided was PMPT staged in four sections and a combination of simple laser curettage, sulcus debridement and de epithelisation and root planning lightly with hard tissue laser and diodes was provided over four appointments. At the fourth appointment full periodontal assessment was redone and all charting later compared, the UR2 and 3 were not mobile anymore and general state greatly improved and stable. In similar cases the next stage would be planned to decide any other advanced regenerative procedures etc.

Case report 11

Figure 81: Pre-treatment

Figure 82: Pre-treatment

Figure 83: Immediate laser PMPT, 90 minutes late

Figure 84: Close up Immediate laser PMPT 90 minutes later

Figure 85: Full arch view post 90 minutes

Figure 86: Full arch view 24 hours later

Figure 87: Post 24 hours

Figure 88: Close up view 24 hours later. Note regrowth- regenration and creeping of gingival tissue

A

Case report 11

This patient another irregular attendee with class III type of periodontitis was treated with the same PMPT protocols and some very dramatic changes were observed within 24 hrs, healing and re growth of tissue seemed to accelerate with one stage sulcular debridement and de-epithelisation provided the patient maintains the oral environment. This is not an unusual occurrence rather a frequently noticed and recorded by us. Sometimes a change can be seen in minutes and we have documented some of these cases in videos or digital imaging.

Summary and conclusions

These are very few instances of laser dentistry in our practice. In the next two parts we will consider other uses relating to regeneration, implants, orthodontics and pain management, among others. To be able to integrate these advance concepts a thorough knowledge of laser physics and cellular mechanisms is essential and imperative.

One of the most frequently asked questions is: Which is the best laser? Our view is it's not the make that's important it's the training and knowledge of what the laser does or does not do and how and what effect it has on the tissues we deal with, and its limitations. A 'laser is a laser' like a car gets from A to B you choose the refinements according to your needs, means, and concepts.

References

A Moritz. Bacterial reduction using diode lasers. Lasers Surg Med 1999: Vol 22: 302-311

Ando Y, Watanbe H, I KshjkawaI. Bactreial effect of Erbium YAG laser on periodontal bacteria. Lasers Med Surg ery 1996;19: 190-200

Ando Y, Watanbe H, I KshjkawaI. Bactreial effect of Erbium YAG laser on periodontal bacteria. Lasers Med Surg ery 1996;19: 190-200

Apel C and Gutnecht N, Bond strength of composites on Er:YAG and Er, Cr: YSGG laser- irraditated enamel. SPIE 1999

Charoenlarpa P, Wanachantararakb, S, Vongsavanc N, Matthews B. Pain and the rate of dentinal fluid flow produced by hydrostatic pressure stimulation of exposed dentin in man. Archives of Oral Biology. 2007; 625-631

Christansen G, Tooth bleaching, State of the art 97. CRA newsletter1997; 21(4):1-4

Coluzzi D J An Overview of Laser Dentistry, Academy of Laser Dentistry 2008

Darbar A. Proc of SPIE vol 6140-61400E-2 2006

Effective calculus removal (Keller U, Hibst R. Proc SPIE 1995) (Aoki A, et al. J Periodontal Res 2000) (Frentzen M, et al. J Periodontol 2002)

Endotoxin on root surfaces significantly reduced with laser compared to hand scaling.(Sugi D, et al. J Conserv Dent 1998) (Sasaki KM, et al. J. Periodontal Res 2002)

Greater fibroblast attachment compared to hand scaled surfaces. (Schoop U, et al. J Oral Laser Appl 2002) (Schwarz F, et al. Lasers Surg Med 2003) (Crespi R, et al. J Periodontol 2006

Greenwall, L. Restorative and Aesthetic Practice 2000; 2(10) 104-109.

Hadley J, Young DA, Eversole LR, Gornbein JA. A laser-powered hydrokinetic system for caries removal and cavity preparation. J Am Dent Assoc. 2000 Jun;131(6):777-85.

Ingber JS, Rose LF, Coslet JG The "Biologic Width"; a Concept in Periodontics and Restorative Dentistry Alpha Omegan 1977; 1: 62-65

Kudoh C., Inomata K., Okayima K., Motegi M, Oshiro T. Low Level Laser Therapy Pain Attenuation Mechanism. Laser Therapy. 1989; (1)1: 3-6

Magne P, Perroud R, Hodges JS, Belser UC. Clinical performance of novel-design porcelain veneers for the recovery of coronal volume and length Int-J-Periodontics-Restorative-Dent, Oct 2000, vol. 20, no. 5, p. 440-57, ISSN: 0198-7569

P. Gingivalis and A. Actinomycetemcomitans significant reduction (Ando Y, et al. Lasers Surg Med 1996) (Folwaczny M, et al. J Clin Periodontol 2002)

Pocket depth reduction (Watanabe H, et al. J Clin Laser Med Surg 1996) (Schwartz F, et al. J Periodontol 2003)

Takamori K, Furukawa H, Morikawa Y, Katayama T, Watanabe S. Basic study on vibrations during tooth preparations caused by high-speed drilling and Er:YAG laser irradiation. Lasers Surg Med. 2003;32(1):25-31.

Takeda FH, Harashima T, Kimura Y, Matsuoka K, Efficacy of Er:YAG Laser irraditaionin removing debris and smear layer on root canal walls. J Endod 1998;24:584-5

Tarnow DP, Magner AW, Fletcher P The Effect of Distance from the Contact Point to the Crest of Bone on the Presence or Absence of theInterproximal Dental Papilla. J Periodontol 1992; 634: 995-996

Ty Hopkins J., Todd A. McLoda, Jeff G. Seegmiller, G. David Baxter Low-Level Laser Therapy Facilitates Superficial Wound Healing in Humans: A Triple-Blind, Sham-Controlled Study J.

Vanini L. Light and color in anterior composite restorations. Pract Periodontics Aesthet Dent 1996, 8(7):673-682

Yamaguchi H, et al. Lipopolysaccharide removal from root surfaces. J Periodontol 1997

Zerman N, Cavalleri G. Traumatic injuries to permanent incisors. Dental Traumatology Volume 9, Issue 2, pages 61–64, April 1993