Introduction to laser dentistry: part one

In the first of a series of articles, **Arun** and **Rita Darbar** explain how lasers can be used beneficially in many aspects of dentistry

Lasers in dentistry today create unique opportunities for the development and application of new technologies. It is hard to imagine that simple photons can change the way in which we practice, from diagnosis and treatment to pain management. The many advantages of using lasers are hard to ignore, such as precision, ease of use and improved outcomes over conventional methods. However a comprehensive understanding of the modality is imperative to avoid damage and reap the benefits of this technology. There is abundant evidence based research that supports this article. We would encourage any dentist interested in introducing a laser into their practice for the first time, to read this research to help better integrate this new technology into their offices.

Education aims and objectives

The aim of this article is to introduce the reader to laser dentistry and address many of the advantages of this type of treatment. It also showcases many case studies that have been performed with the use of lasers.

Expected outcomes

The reader will understand the science behind lasers and how they can be used in diagnosis, pain management and treatment.

Dr Arun Darbar has been using lasers in his dental practice for the past two decades. He has his private practice Smile Creations in Leighton Buzzard, Bedfordshire. He is dedicated to providing cutting edge dentistry to his patients and is an examiner for the Academy of Laser Dentistry and is on the credentialing committee of the British Academy of Cosmetic Dentistry. A founder member of the World Clinical Laser Institute, he continues to find newer applications for the lasers and lectures extensively on the subject. He also runs courses and trains dentists both in the UK and internationally.

Dr Rita Darbar runs her Specialist Orthodontic practice and is also a Specialist Orthodontist at Bedford Hospital. She has had a varied career in dentistry spanning over 30 years, working in the community Dental services, General practice and Hospital services. She enjoys working in a multidisciplinary environment has been interested in laser dentistry for the past eight years and has talked on the subject internationally.

Figure 1: Arun and Mrs Maimann with a first ruby laser

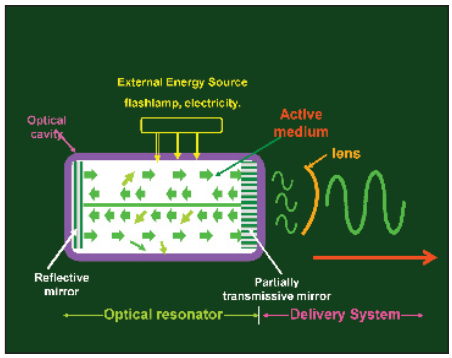

Figure 2: A typical laser-diagrammatic representation

Background

Lasers are used today in everyday life from bar code readers, to robotic surgery, to detection of life on Mars. The word laser is an acronym for 'Light Amplification of Stimulated Emission of Radiation'. Laser light does not exist in nature and is man made. In 1905, Albert Einstein wrote his first paper describing the photoelectric effect where he came up with the idea of a photon that creates laser light. The main difference between ordinary and laser light is that laser light is monochromatic, coherent and collimated whereas ordinary light is multicoloured, the waves are not synchronized and is scattered.

History of dental lasers

In 1960 Theodore Maiman built the first functioning laser using a synthetic ruby crystal medium to produce laser light at 694 nanometers (nm) wavelength in the red region of the electromagnetic spectrum. Even though many physicists were skeptical of his discovery it did however escalate the development of lasers with varying wavelengths, most of which are currently used in dentistry today. Dr Goldman was the first physician to report laser exposure to a vital human tooth and this was used on his brother who was a dentist! A pulsed ruby laser was used (Goldman et al, 1965). All the earlier experiments were with the ruby lasers, Stern 1974, observed that under specific parameters of exposure with a ruby laser there occurred an increased resistance to acid penetration into

enamel and suggested a possible role in caries prevention. Unfortunately, the rise in pulpal temperature led to pulp necrosis which was unacceptable. The first dedicated dental laser was developed by Terry Myers in 1989, an Nd: Yag with a wavelength of 1064nm. It is believed that if this was the first wavelength used in dentistry we would now be using lasers routinely.

Numerous lasers have come on the market since and whereas the earlier units were expensive, bulky and had one dedicated wavelength, today they are affordable, small, portable, mains and battery operated and can have dual wavelengths. Almost a decade ago we were invited to work with the research and development team to convert a soft tissue laser for use as a low level unit with diffusers thereby widening the scope of a diode laser for the relief of pain and for regeneration (Mester et al 1971).

Optical properties

The wavelength of laser light is measured in nanometres (nm). The wavelength is tissue specific and the tissue interaction is dependent on the reaction between the specific wavelength and the optical properties of the tissue. In human tissue the laser light is absorbed by components such as water, hemoglobin, melanin, hydroxyapatie, porphoryns, flavins etc. When a laser light contacts tissue it can be reflected, absorbed, transmitted or scattered. Depending on the photon density used lasers can be photodestructive, photothermeic or photobiomodulative. Hence, with the lasers available today we are not only able to diagnose disease (Alfano 2002, Brancoleon et al 2001), remove diseased tissue, but to weld tissue (Bass and Treat 1996, Reiss 2001) and help with the regeneration. Currently, lasers in dentistry are widely used in Diagnosis and Treatment, which can be all laser or laser assisted.

Diagnosis

Optical imaging is fast becoming a reliable tool for diagnosis and utilises these properties and that of fluorescence for diagnosis and treatment of disease. Most imaging techniques used today are focused on anatomical structures whereas biomedical imaging focuses on the cellular level making it possible to detect disease in the early stages (Gillenwater et al 1998). An example is the use of blue light by the Velescope to improve visualisation of the oral mucous membrane to detect early signs of dysplasia. A red light 690nm laser is used with a feedback mechanism, using fluorescence through enamel and dentine and with a reflective probe giving an analog or digital score, for dental caries detection e.g. Diagnodent.

Solid state	Gas	Dye	Semiconductor diode
YSGG lasers	CO_2	flash lamp-pumped	812nm
Erbium Chromium	Argan	Argan-pumped	980nm
YAG lasers - all	Excimers		488/514nm
Erbium	Helium/neon		632nm
Holmium	Krypton		various
Neodynium			
Other Rod lasers			
Ruby			
Alexandrite			
Soft lasers (various diodes). Used for photodynamic therapy, biostimulation, desensitisation, wound healing, pain control			

Figure 3: Types of lasers in dentistry

Figure 4: Schematic representation of tissue fluorescence
Normal (healthy) tissue fluorescence
- Shining an excitation light on the tissue causes it to emit fluorescence
- Colour is characteristic of the combination of the fluorophores in the tissue



Figure 5: Schematic representation of tissue fluorescence
Abnormal tissue fluorescence
- Changes in tissue fluorescence can help determine areas where molecular/structural changes have occured

Therapeutics

Recent developments in Photodynamic Therapy uses a laser light with a photosensitive dye to activate the formation of singlet oxygen for its bactericidal effect (Henderson 1992) in periodontal pockets and in the root canals. This has now been extended for use in peri-implantitis

The most commonly used lasers in dental practice today are diodes. These are soft tissue only lasers and generally have wavelengths between 810nm-1064nm. They can be used for haemostasis, incision and excision of soft tissue for indications including crown lengthening, sulcular debridement, troughing before taking an impression, fraenectomy and implant recovery. Due to their high absorption in haemoglobin it makes them very effective for coagulation. Their affinity for water also makes

Figure 6: Unerupted central incisor preop

Figure 7: Laser exposed central incisor- hard tissue laser was used

Figure 8: Bracket attached to the tooth

Figure 9: Tooth in alignment with rest of the arch

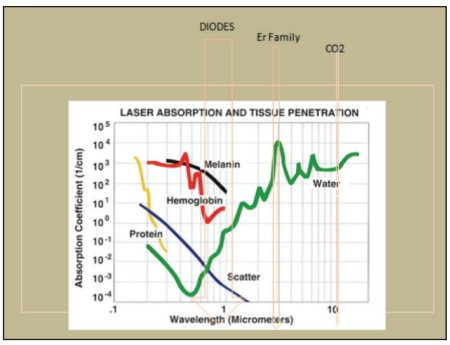

Figure 10: Wavelength absorption characteristics

Figure 11: Laser whitening preop.

Figure 12: Laser whitening first stage postop

Figure 13: Worn and stained Composites

Figure 14: Laser prepped enamel surface

Figure 15: Finished composite restorations immediate post op

Figure 16: Aggressive periodontitis preop

Finger 17: Laser curettage. Post Op

them effective for tissue ablation. The diode is set to compete with the electro-surgery unit as it has the additional benefits of being compatible to use around metal and the additional uses such as periodontal application (Aoki et al 2008), desensitisation (Ladalardo et al 2004), tooth whitening, treatment of TMD (Pinheiro et al 1998) and ulcers. The flexibility of the fibre also makes it useful for those hard to reach areas like the root canal (Gutknecht et al 2004) and periodontal pockets. We must not forget the advantages for the patients experiencing less pain and better healing compared to purely a hot knife.

There is a paradigm shift when using the diode laser as the tip can be in contact or non-contact. The laser can be initiated or uninitiated depending on the procedure to be performed. The beam can be focused or defocused, it can be in a continuous mode or a pulsed mode (and/or gated modes) and today we are looking

Figure 18: Crown lengthening or gingival recontouring preop

Figure 19: Temporary crown in place

Figure 20: Tissue at prep site well maintained

Figure 21: Definitive long-term restorations in place at fit appointment

Figure 22: Unerupted canine soft tissue exposure preop

Figure 23: Soft tissue exposure immediate postop

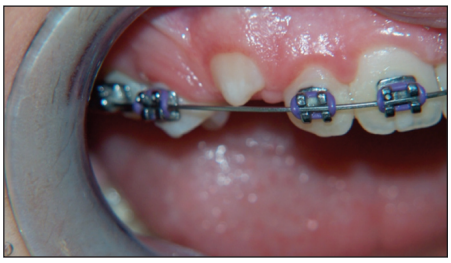

Figure 24: Canine eruption at 10 day review. Post op

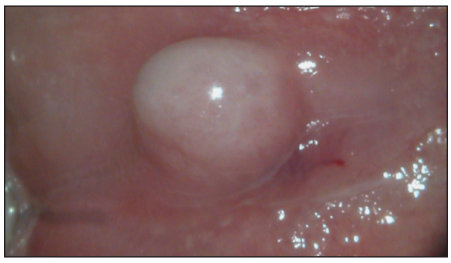

Figure 25: Irritation fibroma preop

Figure 26: Fibroma stabilisation

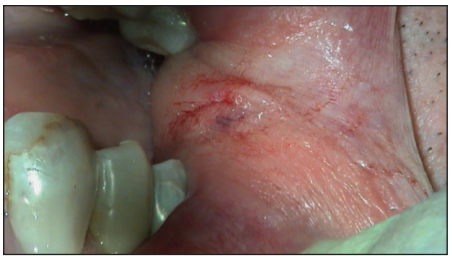

Figure 27: Fibroma excision site immediate post op

Figure 28: Painful traumatic ulcer pre op

Figure 29: Healed ulcer site

at super pulsed and micro second pulsing. A clear understanding of the effects of each will determine the energy delivered to the tissue.

'The Erbium family'

These include the Er:Yag-2940 nm and ER,Cr: Y.S.G.G. 2780 nm-both are typical hard tissue lasers with a high affinity for water and hydroxyapatite. They can also be used as soft tissue lasers. They are similar in action with slight variation in absorption characteristics but in practical terms appear to have similar properties.The concentrated laser energy in the water content leads to mini explosions thereby ablating hard tissue like enamel and dentine. As the tips are end cutting, the most efficient cut is at about 90 degrees to the tooth surface to be removed.

Another added benefit is that the smear layer is removed (Takeda et al 1999) which would increase the bond strength to the tooth structure and the cavity preparation is disinfected. Patients also report less or no pain during the procedure which reduces the need for a local anaesthetic which could be attributed to the non contact mode as pressure from the high speed turbine affects the hydrostatic pressure in the dentinal tubules resulting in pain (Charoenlarp et al 2007).

This wavelength is also suitable for soft tis-

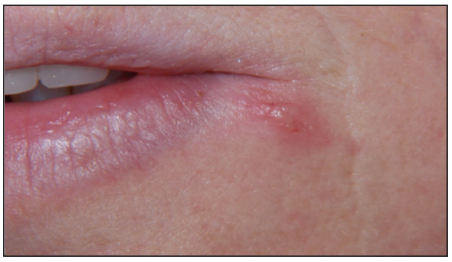

Figure 30: Herpetic cold sore chronic sufferer

Figure 31: Herpetic lesion two days later

Figure 32: Healed site few weeks later

sue ablation and for cutting bone safely which makes it one of the most popular lasers for general dental practice.

Carbon dioxide (CO_2) laser

This laser with a wavelength of 10600 nm found use with the Maxillo-facial surgeons. Due to the high absorption in water it cuts soft tissue easily leaving a clean field (Fuller 1988) with a char layer that acts as a bandage therefore reducing the need for sutures and decreases scarring. As it operates in a non-contact mode there is less mechanical trauma and makes access easy in the confined oral cavity. They are most often used for incisional and excisional biopsies and to remove hyperplastic tissue.

The CO_2 lasers were dubbed the king of cutters, today we use super pulsed high intensity lasers that give a clean cut without the char layer formation. In recent years the use of frequency doubled Nd; Yag with a KTP crystal and has replaced some of the CO_2's as they are smaller and cheaper. A CO_2 with a wavelength of 9500-9600nm is also being investigated for hard tissue ablation.

The use of magnification in the form of loupes and microscopes, have broadened the horizons for dental procedures as the higher demands for clinical expertise is not within the normal visual field. As the laser works at a cellular level it complements the use of magnification and illumination to enable precise and minimally invasive procedures. On average the laser removes three to five cell layers at a time.

The delivery system is also ergonomically designed to mimic the turbine handpiece for easier adaption. They are designed to reduce the need for the high speed turbine which is patient driven and the use of the scalpel for soft tissue incision and excision as there is evidence of accelerated inflammation, faster and good quality healing with reduced complications as a result of the photobiomodulatory (Bjordal et al 2006, Kudoh et al 1989, Hug and Hunter 1991, Karu 1988) effects.

Considering the many advances in lasers in medicine over the past two decades and their widespread use in Opthalmology and Dermatology the uptake in Dentistry remains slow. This could be attributed to the cost, however this is now comparable to other technologies used in dental practices and since the development of diode lasers a very affordable entry-level option. Adequate training is the key for successful integration of lasers into any general or specialist dental practice.

The next article will discuss the properties of light and how low level lasers are used today in medicine and dentistry. This will be followed by hard and soft tissue applications with tips on how to adjust parameters to get consistent and predictable results.

References

Alfano,R.R Optical Biopsy IV, SPIE Proc. Vol. 4613, SPIE, Bellingham 2002

Aoki A, Mizutani K, Takasaki AA, Sasaki KM, Nagai S, Schwarz F, Yoshida I, Eguro T, Zeredo JL, Izumi Y. Current status of clinical laser applications in periodontal therapy. Gen Dent 2008;56:674-87

Bass,L. S.,Treat, M. R. Laser tissue welding: A comprehensive Review of Current and Future Applications. Laser Surgery and Medicine. Principles and Practice, Wiley-Liss, New York, 1996:381-415

Bjordal JM, Johnson MI, Iversen V, Aimbire F, Lopes-Martins RA. Photoradiation in acute pain: a systematic review of possible mechanisms of action and clinical effects in randomised placebo controlled trials. J Photomed Laser Surg; 2006 24(2):158-168

Brancoleon,L et al. In vivo Fluorescence Spectroscopy of Nonmelanoma skin cancer. Photochem.Photobiol.2001;73:178-183

Charoenlarp P, Wanachantararak S, Vongsavan N, Matthews B. Pain and the rate of dentinal fluid flow produced by hydrostatic pressure stimulation of exposed dentine in man. Arch Oral Biol. 2007 Jul;52(7):625-31.

Fuller TA. Fundamentals of lasers in surgery and medicine. In: Dixon JH ,ed. Surgical application of lasers, 2nd ed. Chicago: Year Book Medical Publishers, Inc; 1988:16-33.

Gillenwater A, Jacob R, Ganeshappa R, Kemp B, El-Naggar AK, Palmer JL, Clayman G, Mitchell MF, Richards-Kortum R. Noninvasive Diagnosis of Oral Neoplasia Based on Fluorescence Spectroscopy and Native Tissue Autofluorescence Arch Otolaryngol Head Neck Surg. 1998; 124:1251-1258

Gutknecht N, Franzen R, Schippers M, Lampert F. Bactericidal effect of a 980nm diode laser in the root canal wall dentin of bovine teeth. J of Clinical Laser Medicine and Surgery 2004;22:9-13

Henderson B. How does Photodynamic Therapy Work? J Photochem.Photobiol. B: Biol.1992;55:145-157

Hug DH, Hunter JH. Photomodulation of enzymes. J of Photochem and Photobiol B: Biol 10:3-22,1991

Karu T. Molecular mechanism of low power laser therapy. Lasers life Science.1988;2:53-74

Kudoh C., Inomata K., Okayima K., Motegi M. Oshiro T. Low Level Laser Therapy Pain Attenuation Mechanism. Laser Therapy. 1989; (1)1: 3-6

Ladalardo TC, Pinheiro A, Campos RA, Brugnera Júnior A, Zanin F, Albernaz PL, Weckx LL., Laser therapy in the treatment of dentine hypersensitivity. Braz Dent J. 2004;15(2):144-50.

Maiman T H. Stimulated optical radiation in ruby. Nature 1960; 187: 493–494.

Mester E, Spiry T, Szende B. Effect of Laser Rays on Wound Healing, Am. J. Surg. 1971;122:532-535

Myers T D, Myers W D, Stone R M. First soft tissue study utilising a pulsed Nd YAG dental laser. Northwest Dent 1989; 68: 14–17.

Pinheiro AL, Cavalcanti ET, Pinheiro TI, Alves MJ, Miranda ER, De Quevedo AS, Manzi CT, Vieira AL, Rolim AB. Low-level laser therapy is an important tool to treat disorders of the maxillofacial region. J Clin Laser Med Surg. 1998 Aug;16(4):223-6

Reiss, S. M., Laser Tissue Welding: The leap from Lab to the Clinical Setting. Biophonics Int. 2001:36-41

Takeda FH, Harashima T, Kimura Y, Matsumoto K. A comparative study of the removal of smear layer by three endodontic irrigants and two types of laser. Int Endod J. 1999 Jan;32(1):32-9.

A